

Synchondrotic Fracture of Odontoid Treated by Cervical Collar after Complication of Anterior Screw Fixation: A Case Report and Review of Literature

Yusuf Kurtulus Duransoy, Mesut Mete, Ulkun Unsal Unlu, Mustafa Barutcuoglu, Mehmet Selcuki

Department of Neurosurgery, Celal Bayar University, Faculty of Medicine, Manisa, Turkey

ABSTRACT

Odontoid fractures are rarely seen in childhood. Treatment is different than in adults and diagnosis is difficult. Our case was a 5-year-old male. He was admitted to emergency department after a traffic accident. He had neurological deficits. We noticed odontoid fracture and anterior dislocation on cervical computed tomography (CT). Odontoid screw fixation was done via anterior approach. However, the odontoid screw was removed in the postoperative early period due to breakage of the front part of C2 corpus and he was kept in cervical collar. In radiological follow-up, the odontoid fracture healed with conservative measures. Unlike adults, childhood odontoid fractures result in high rates of solid fusion with external fixators. These fractures are called “joints shift” or “synchondrotic slip” and surgery should be planned if nonunion develops despite conservative treatment or if there is compression of neural structures, unstable spine injuries, odontoid dislocations greater than 4 mm, type IC synchondrotic fracture and neurological impairment due to brain or spinal cord injury, as well as multiple trauma. Management of synchondrotic fracture of the odontoid is still controversial. Both surgical stabilization and closed reduction plus external immobilization could be the treatment of choice for unstable odontoid fracture in this age group.

KEY WORDS: Anterior odontoid screw fixation, Childhood odontoid fracture, Epiphyseal slip, Odontoid joints shift, Synchondrotic fracture, Synchondrotic slip

INTRODUCTION

Pediatric upper cervical spine injuries (PUCSIs) are rare and constitute between 0.6 and 9.5% of all cervical spine injuries (7). Upper cervical spine injuries (UCSIs) are different in children than adults due to anatomical differences of the developing spine. In children, the large mass of the head, horizontal facet joints and wedge shaped vertebral bodies are the main culprits of upper spine injuries. Furthermore interspinous ligaments are elastic and neck muscles are weak (7, 16, 20, 22, 28). All these features predispose children to UCSIs, and fractures of the odontoid are the most common lesions seen in upper cervical region in the childhood (13). The

mechanism of injury is variable. While the most common trauma reason for cervical spine injuries is the motor vehicle accidents in younger children, sporting activities are more often seen in older people and adolescents (5). The synchondrosis of the axis closes after seven years of age (8, 13). Thus, low energy injuries might cause more odontoid process fractures in young children (at the age of 7 and under) than older children and adults (13). Hosalkar et al. defined four types of odontoid fracture in younger children for open synchondrosis (13). Type I is odontoid fracture at the level of the synchondrosis. Type I is divided into three subtypes. Type IA is fractures of the synchondrosis with less than 10% displacement, type IB fracture of the synchondrosis is with displacement of

10% to 100% and type IC fracture of the synchondrosis is with displacement of more than 100%. Type II odontoid fracture is above the level of synchondrosis.

Anderson and D'Alonzo classified odontoid fractures into 3 types with experience of 60 patients. Type I is an oblique fracture through the upper part of the odontoid process itself. Type II is a fracture at the junction of the odontoid process with the vertebral body of the axis. Type III is total fracture through the body of the atlas (1). This classification is more appropriate for older children (over 7 years old age) and adults according to Hosalkar et al (13). The difference in the mechanism of the injury makes a difference in both diagnosis and treatment. The general approach includes conservative treatments external immobilization such as halo vest, Minerva cast, SOMI brace and cervical collar. In some special cases, anterior screw fixation or posterior C1-2 fusions should be applied (8, 9, 12, 14, 17, 25, 26, 27, 28). In this article we presented a 5-year-old male patient with type IC synchondrotic fracture of the odontoid. We performed anterior odontoid screw fixation, but the screw was removed by a second operation because the front part of the C2 corpus was broken after the insertion of screw, and the patient was put in cervical collar. In the follow-up period, solid fusion was completed.

CASE REPORT

A five-year-old male was admitted to our emergency department after a traffic accident. He was confused, agitated and had tetraparesis. He had a deep incision on the right side of the neck that contained pieces of

glass. Cervical X-ray and cervical tomography showed anterior displacement and odontoid fracture (Type IC synchondrotic fracture according to Hosalkar) (Figure 1A, B).

Cranial CT showed hemorrhagic contusion on the right side of the 4th ventricle in the cerebellum. He was intubated at the operation theatre to maintain better ventilation and ensure immobilization by reducing the head movements caused by agitation. In the meantime, we determined that the sequence of cervical vertebrae was normal. Anterior displacement improved in the extension position as detected by radioscopy (Figure 2).

After the right side of neck has been cleaned and washed up at the operation theatre, we also noticed a deep incision extending to the sternocleidomastoid muscle (SCM). These factors led to urgent surgery for anterior screw fixation because of the instability of the type of odontoid fracture. During the operation, we observed cerebrospinal fluid (CSF) leakage from the site of the odontoid fracture line. Anterior fixation was performed with an transodontoid screw by using a special hand device designed by the first author. On the postoperative first day, his neurological deficits had fully recovered and the first day was uneventful. However, at the postoperative 15th day follow-up cervical CT showed that the odontoid screw had broken the front part of the C2 body, leading to instability and possible danger to nervous tissue elements, and the odontoid screw was removed in the second operation (Figure 3A,B). This complication stemmed from the lack of a suitable screw

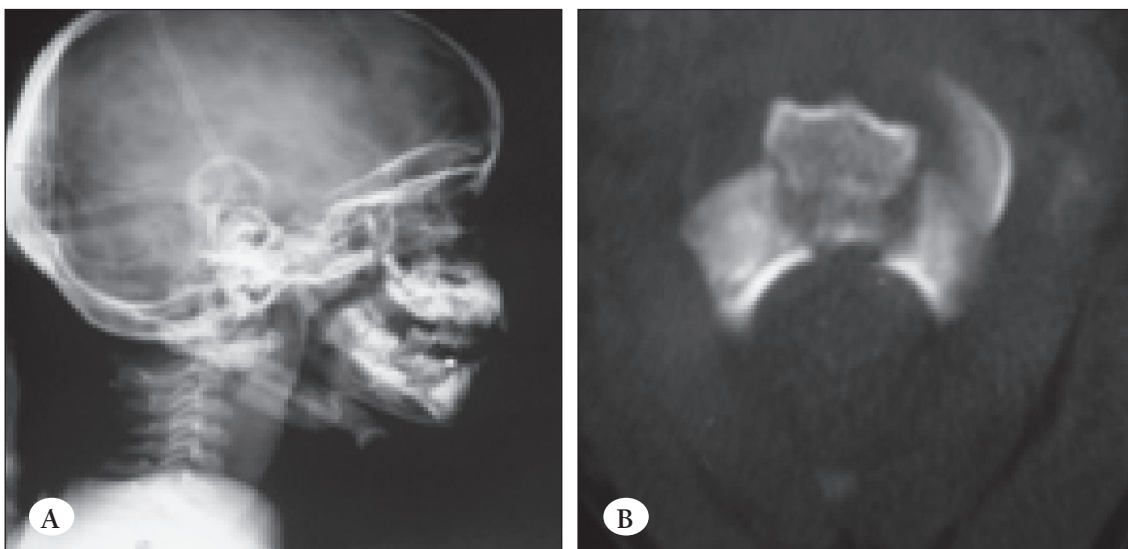


Figure 1: Cervical X-ray showing anterior displacement and odontoid fracture (Type IC synchondrotic fracture according to Hosalkar) (1A). Cervical tomography showing anterior displacement and odontoid fracture (Type IC synchondrotic fracture according to Hosalkar) (1B).

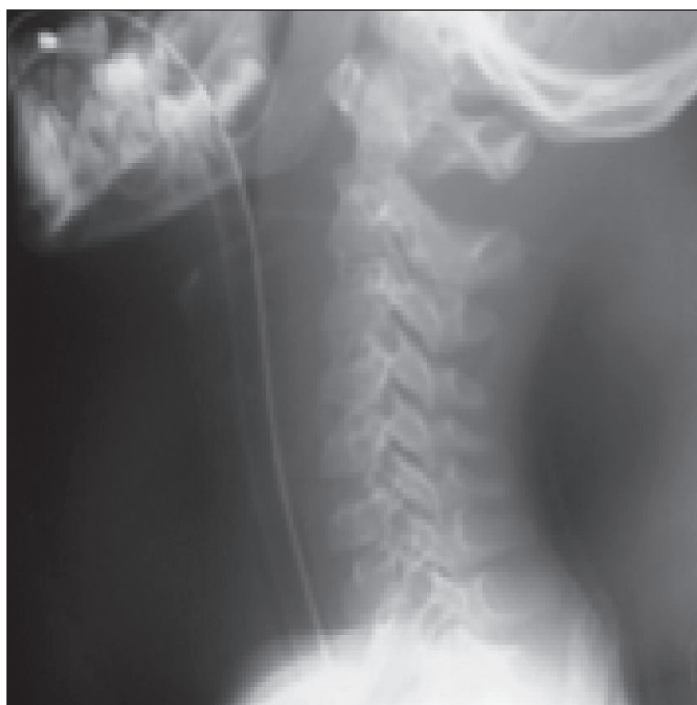

Figure 2: Improvement of odontoid displacement and normal sequence of cervical vertebrae in the extension position.

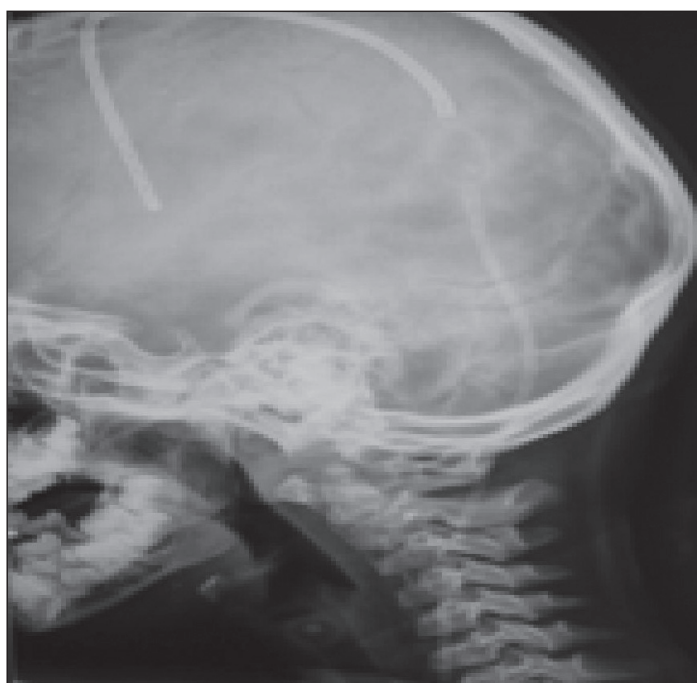

Figure 4: Cervical x-ray showing beginning of fusion at fractured pieces and V-P shunt materials.

size in the operation set. The screw used was thicker than the normal pediatric odontoid.

The patient was followed with a SOMI brace. In the following days a decubitus ulcer occurred under the chin so

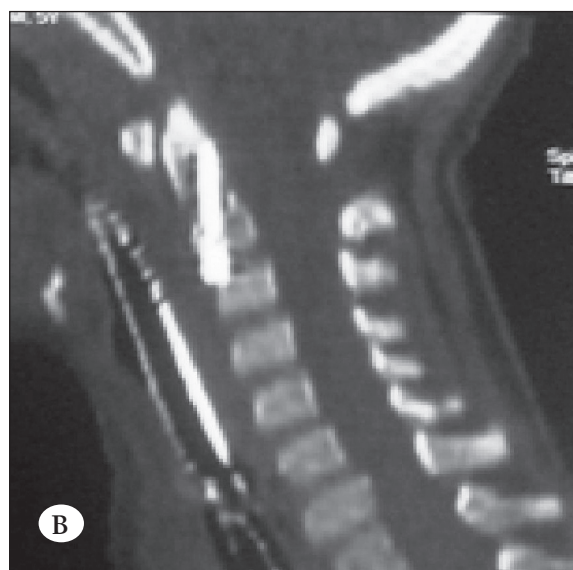
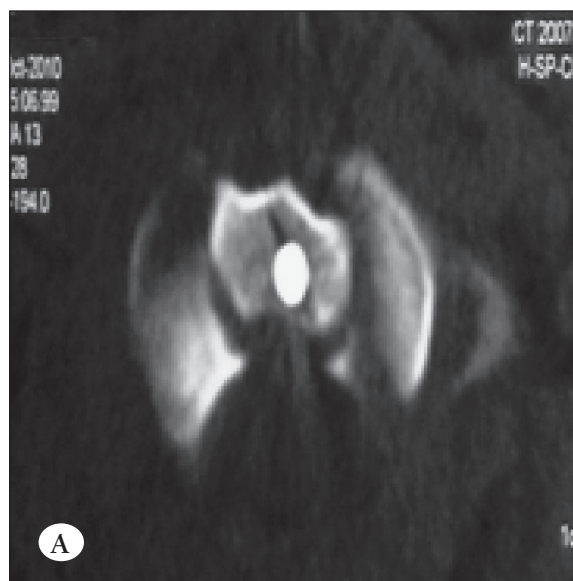


Figure 3: Axial section of cervical CT showing broken odontoid screw at the front part of the C2 body (3A). Sagittal section of cervical CT showing broken odontoid screw at the front part of the C2 body (3B).

the SOMI brace removed and a cervical collar fitted. Eleven days after the second operation a CSF fistula occurred at the incision and *Staphylococcus aureus* infection was detected on CSF cultures. Follow-up cranial CT showed hydrocephalus and an external ventricular drainage was inserted. Five weeks later, a ventriculoperitoneal shunt applied. Although we planned a SOMI brace, x-rays and cervical CT 12 weeks from trauma showed that fusion of the fractured pieces had already begun (Figure 4).

In the follow-up 12 months later with a cervical collar, x-ray showed that solid fusion has been completed (Figure 5).

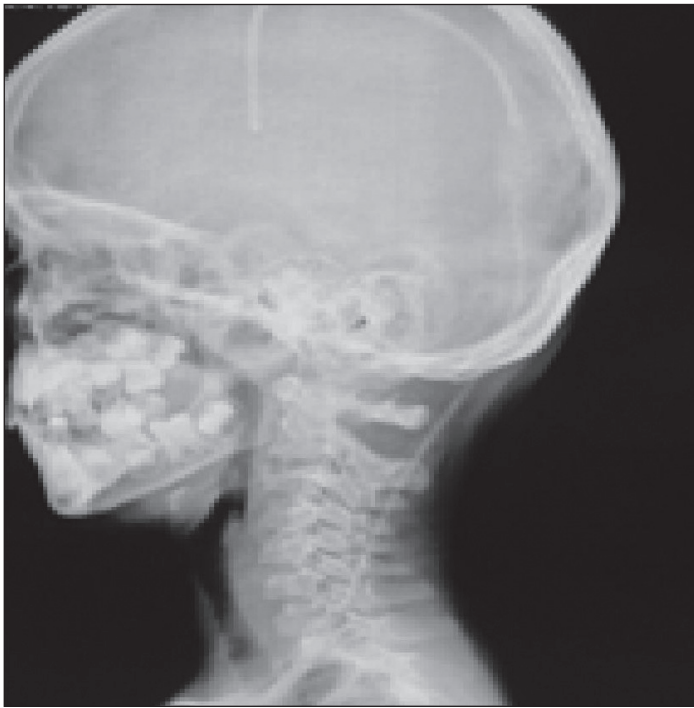

Figure 5: Cervical x-ray showing completed solid fusion .

DISCUSSION

Pediatric upper cervical spine injuries (UCSIs) are rare and constitute between 0.6 and 9.5% of all cervical spine injuries (7) and approximately 40 to 60% of all pediatric spine injuries occur in the cervical region (16). Pediatric odontoid fracture is one of the more common types of cervical spine fractures in children younger than 7 years of age (8). The pathological mechanism in pediatric odontoid fractures has been described as “synchondrotic slip” because of open synchondroses of the axis. Synchondroses of the axis close when the child is 7 years old according to Hosalkar and Fassett (8, 13), 10 years old according to Schwarz, Wang and Anderson D’Alonzo (1, 22, 28), and 6 years old according to Uemura and Godard (9, 26). The management of fractures of the odontoid process and axis in childhood is still controversial.

Nourbakhsh et al. reported that conservative management provides better results for odontoid fractures with <4-6 mm displacement than in fractures with > 4-6 mm. Although the fusion rate of external immobilization is the same with operative treatment in anterior displacement, surgery should be considered as the first choice of treatment in posterior displaced fractures. Same authors have reported that conservative management can be as effective as surgery in young patients (18). Fassett

et al. noted 93% fusion with external immobilization and reported that most fractures are initially treated with reduction and external orthosis (8). Blauth et al. and Fassett et al. suggested that 3 months of external immobilization is sufficient for union (8, 4). Hosalkar et al. treated 15 children with external immobilization in their 17 patients with odontoid fractures in an open basilar synchondrosis series. One died and the other underwent atlantoaxial posterior fixation and fusion. In the same study with 6 closed basilar synchondrosis odontoid fractures they reported good fusion for 4 patients with external immobilization and for 2 patients with posterior C1-2 fusion (13). Fassett et al. reported 4 of 55 children treated surgically. These surgeries consisted of one odontoid screw fixation, one temporary C1-2 posterior wiring combination with anterior bone graft and two cases of C1-2 posterior arthrodesis. All four patients had fusion after surgery. They treated the remaining 45 patients with external stabilization. Fusion was seen in 42 of 45 patients without surgery. Another three patients out of 45 underwent surgical stabilization with posterior C1-2 arthrodesis (8). Anderson and D’Alonzo reported 5 children with odontoid fractures among 60 patients in their series. One of the 5 patients died in the first week of injury. Four were treated surgically, and one of these by C1-C2 posterior primary wiring and fusion with graft. After surgery, the grafts resorbed and the wire broke but the fracture was stable with establishment of bony union. The remaining patients (respectively 5 years, 5 years and 6 years old) were all treated by traction for six weeks followed by Minerva casts. They concluded that type II lesions might have a better prognosis in children because of epiphyseal separations and a chance should be given for conservative treatment in children under the age of 10 with odontoid fractures with surgery being reserved for nonunion cases (1). Our patient was followed up for 3 months as an inpatient in a cervical collar after removing the odontoid screw with the second operation and we noted beginning of fusion in cervical roentgenograms.

Although the main treatment is conservative, surgery might be the first method in some cases. The surgical approach might be anterior screw fixation or posterior C1-2 fusion. Irreducible deformities, unstable spine injuries, compression of neural structures (16), odontoid dislocations greater than 4 mm (28), type 1C odontoid fractures (13), neurological impairment due to brain or spinal cord injury, as well as multiple injuries

(22) are indications for surgery. Surgery should also be the treatment method in nonunion after conservative treatment (1, 8, 14, 26, 28). We performed anterior odontoid screw fixation because of neurological deficits, odontoid dislocation anteriorly of more than 10 mm and agitation of the patient due to cervical trauma and hemorrhagic cerebellar contusion. However, at postoperative 15th day follow-up cervical CT showed that the odontoid screw had broken the front part of the C2 body, which means instability and possible danger to nervous tissue elements, and the odontoid screw removed in second operation. He was followed in a SOMI brace and cervical collar and solid fusion was performed after 12 months despite complicated anterior odontoid screw fixation due to inappropriate screw size.

Many authors have used a posterior surgical approach for odontoid fractures in childhood. Duhem et al. surgically treated a 15-year-old child with odontoid fracture by posterior C1-2 wiring. They demonstrated fusion in the follow up examination (7). Anderson et al. reported good fusion in 4 pediatric patients after posterior fixations and C1-2 fusions in os odontoideum cases (2). Reinges et al. treated a synchondrotic disruption of the odontoid process in a 15-month-old girl with C1-2 interlaminar wiring without grafting. At follow-up 1 year after surgery, radiographic examination demonstrated fusion and stability (21). Schippers et al. reported girls aged 2 years and 9 months with odontoid fracture treated with interlaminar wire fixation with grafting (8). Hubbard reported a 2-year-old boy with odontoid epiphyseal slip treated with posterior surgical fusion (21, 26). Uemura et al. treated a 27-month-old girl with odontoid fracture by C1-2 posterior wiring and grafting. Price in 1960, Diekema and Allen in 1988 used C1-C2 wiring and fusion in childhood odontoid fractures (26). Haque et al. treated 3 os odontoideum cases (respectively 4 years, 11 years and 11 years old) by C1-2 transarticular screw (12). Viswanathan et al. treated a 12-year-old child with ossiculum terminale by posterior C1-2 fusion (27). Swoboda et al. reported C1-2 fusion and transodontoid screw fixation to 7-year-old boy who had traumatic ossiculum terminale. They determined instability after removing of dorsal implants due to breaking of transodontoid screw, and atlantoaxial fusion performed again (25). Mc Grory et al. treated 6 children (respectively 3 years, 2 years, 14 years, 4 years, 6 years and 2.5 years old) with odontoid fracture with posterior fusion. On radiographical follow-up, 3 had

stable, and 2 had slightly unstable odontoid fractures. The last one was not available for radiological follow-up (17). Odent et al. performed surgery in 3 of 15 children with posterior C1-2 wiring who had odontoid fracture (19).

Posterior fixation causes deformity during growth of bone at fixed levels and this is called the “crankshaft” phenomenon (10). Blauth et al. performed posterior C1-C2 fixation in one child under 3 years of age. They removed the posterior fixation wire after 5 months. Follow-up radiological examination showed normal bony growth of the odontoid (4). A lesson learned from this study is the removal of the posterior wiring system after a while in order not to cause disordered growth of the odontoid process. Posterior fusion reduces cervical rotation by 50% and flexion-extension by 10% (14, 23). Gluf and Brockmeyer reported a 10.4% complication rate for pediatric C1-2 transarticular screw placement with two vertebral artery injuries in their series of 67 patients (12). Haque et al. reported that the shape and size of the pediatric C-1 lateral mass can make screw placement difficult and may cause vascular complications (12).

Another choice of treatment is anterior transodontoid screw fixation of odontoid fracture as reported by the authors (4). Blaut et al. also point out that rigid fixation part of the odontoid fracture does not interfere with bone growth (3). Jones et al. reported a 15-year-old boy with missed odontoid fracture. The nonunion was asymptomatic for 2 years until the second injury. Anterior screw fixation was performed after conservative treatment due to no sign of union after 3 months from the second injury. Five months after screw fixation they noticed that fusion had occurred and they suggested that anterior screw fixation should be the next step in case of nonunion with conservative measures (14). Zapalowicz et al. treated a 12-year-old boy with displaced Type III odontoid fracture successfully by direct anterior screw fixation. Healing of the fracture was confirmed by roentgenograms at follow-up examinations. The range of motion of the cervical spine examined 6 months after surgery was normal (29). Wang et al. treated 3 children (respectively 4 years, 10 years and 14 years old) with odontoid type II fractures with an odontoid screw and 4 pediatric (respectively 9 years, 11 years, 14 years and 14 years old) os odontoideum patients with posterior C1-2 screw in a series of 16 patients. They determined fusion in follow-up cervical x-rays in all patients. Wang et al. reported that

unstable cases or odontoid dislocations greater than 4 mm could be treated successfully by odontoid screws if the transverse ligament was intact. (28). Sung operated on a 15-year-old male with odontoid type II fracture and noted fusion. The author reported that anterior screw fixation should be a treatment method in type II odontoid fracture (23). Godard et al. reported neurological improvement and good fusion in a 2.5-year-old child with unstable odontoid fracture after anterior osteosynthesis (9). Apfelbaum et al. reported direct anterior screw fixation for odontoid nonunited fracture in 15-year-old child but they did not comment about union of fracture (14). Brockmeyer reported on a case of odontoid screw use in a 14-year-old child (9). Blauth et al. treated 3 children (9 months, 15 months and 18 months old) by anterior odontoid screw and fusion was seen in all children (3). Junge et al. reported successful anterior odontoid screw application to a 3-year-old child with odontoid fracture (22). Table-1 shows a review of the literature for anterior odontoid screw fixation in patients under 16 years old.

Lee et al. noted 90% fusion in their 20 adult patients (15). Subach documented a 96% fusion rate and 8% complication rate in their study with adult patients (24). This technique has several advantages over posterior C1-C2 fusion. It is less traumatic because the exposure is obtained through tissue planes and this technique does

not require atlantoaxial arthrodesis and does not interfere with the cervical motion (11). We performed anterior odontoid fixation successfully. Although control cervical tomography showed breaking of the front part of the C2 corpus, this complication stemmed from the lack of suitable screw size in the operation set and the screw was removed. Nevertheless, fusion was completed by cervical collar.

Anterior screw fixation is contraindicated in patients with transverse ligament disruption, cervical kyphosis, atlantoaxial joint injuries (if the fracture line parallel to the screw trajectory), cervical spondylosis. and obesity which makes it difficult to obtain optimum screw trajectory (19). This fixation should not be used in osteoporotic bone and pathological fracture (18).

CONCLUSION

1. The mechanism, diagnosis and treatment of odontoid fractures in children under 7 years of age are different than adults and older children.
2. In this age group, there is still no consensus for the management of synchondrotic fracture of the odontoid. This pathology could be treated conservatively, but surgical stabilization could be another treatment method, if conservative treatment fails.

Table 1: Literature review of Anterior Odontoid Screw Fixation under 16 years old

Author-Year	Age	Approach	Result
Junge-1994	3 years	AOSF	Successful fusion
Brockmeyer-1995	14 years	AOSF	N/F
Swoboda-1995	7 years	AOSF	Nonfusion
Blauth-1998	15 months	AOSF	Successful fusion
	18 months	AOSF	Successful fusion
	9 months	AOSF	Successful fusion
Wang-1999	3 years	AOSF	Successful fusion
	10 years	AOSF	Successful fusion
	14years	AOSF	Successful fusion
Godard-1999	2.5 years	AOSF	Successful fusion
Apfelbaum-2000	15 years	AOSF	N/F
Jones-2004	15 years	AOSF	Successful fusion
Zapałowicz-2004	12 years	AOSF	Successful fusion
Sung-2005	15 years	AOSF	Successful fusion
Fassett-2006	Under 7 years	AOSF	Successful fusion

AOSF: Anterior Odontoid Screw Fixation, N/F: Non-followed.

3. In case of nonunion after a considerable time period (3 months) with conservative treatment, surgical intervention should be preferred. Not just nonunion cases, but cases with compression of neural structures, unstable injuries, progressive neurological deficits and odontoid dislocations greater than 4 mm also require surgical intervention as soon as possible to prevent undesirable injuries to the neural tissues.

REFERENCES

- Anderson L D, D'Alonzo R T: Fractures of the Odontoid Process of the Axis. *J Bone Joint Surg Am* 56:1663-1674, 1974
- Anderson R C E, Ragel B T, Mocco J, Bohman L E, Brockmeyer D L: Selection of a rigid internal fixation construct for stabilization at the craniovertebral junction in pediatric patients. *J Neurosurg* 107: 36-42, 2007
- Blauth M, Schmidt U, Lange U: Verletzungen der Halswirbelsäule bei Kindern Unfallchirurg 101(8):590-612, 1998
- Blauth M, Schmidt U, Otte D, Krettek C: Fractures of the odontoid process in small children: biomechanical analysis and report of three cases. *Eur Spine J* 5:63-70, 1996
- Brown R L, Brunn M A, Garcia V F: Cervical Spine Injuries in Children: A Review of 103 Patients Treated Consecutively at a Level 1 Pediatric Trauma Center. *Journal of Pediatric Surgery* 36(8):1107-1114, 2001
- Dickerman R D, Morgan J T, Mittler M: Circumferential Cervical Spine Surgery in an 18-Month-Old Female with Traumatic Disruption of the Odontoid and C3 Vertebrae. *Pediatric Neurosurg* 41:88-92, 2005
- Duhem R, Tonnelle V, Vinchon M, Assaker R, Dhellemmes P: Unstable upper pediatric cervical spine injuries: report of 28 cases and review of the literature. *Child's Nerv Syst* 24: 343-348, 2008
- Fassett D R, Mc Call T, Brockmeyer D L: Odontoid synchondrosis fractures in children. *Neurosurg Focus* 20(2):E7, 2006
- Godard J, Hadji M, Raul J.S: Odontoid fractures in the child with neurological injury. Direct anterior osteosynthesis with a corticospogious screw and literature review. *Child's Nerv Syst* 13(2):105-107, 1996
- Gore PA, Chang S, Theodore N: Cervical Spine Injuries in Children: Attention to Radiographic Differences and Stability Compared to Those in the Adult Patient. *Semin Pediatr Neurol* 16:42-48, 2009
- Grazino G, Jaggars C, Lee M, Lynch W: A comparative study of fixation techniques for type II fractures of the odontoid process. *Spine* 18: 2383-2387, 1993
- Haque A, Prisca A V, Sklar F H, Swift D, Weprin B Sacco D: Screw fixation of the upper cervical spine in the paediatric population. *J Neurosurg Pediatrics* 3:529-533, 2009
- Hosalkar H.S, Greenbaum J.N, Flynn J.M, Cameron D.B, Dormans J.P, Drummond D.S: Fractures of the odontoid in children with an open basilar synchondrosis. *J Bone Joint Surg* 91-B: 789-796, 2009
- Jones A, Mehta J, Fagan D, Ahuja S, Grant A, Daves P: Anterior Screw Fixation for a Pediatric Odontoid. *Spine* 30:28-30, 2004
- Lee SH, Sung JK: Anterior odontoid fixation using a 4.5-mm Herbert Screw: the first report of 20 consecutive cases with odontoid fracture. *Surgical Neurology* 66: 361-366, 2006
- Mc Call T, Fassett D, Brockmeyer D: Cervical Spine Trauma in children: a review. *Neurosurg Focus* 20(2):1-8, 2006
- McGrory B J, Klassen R A: Arthrodesis of the cervical spine for fractures and dislocation in children and adolescents. A long-term follow-up study. *J Bone Joint Surg Am* 74:1606-1616, 1994
- Nourbakhsh A, Shi R, Vannemreddy P, Nanda A: Operative versus nonoperative management of acute odontoid Type II fractures: a meta-analysis. *J Neurosurg Spine* 11:651-658, 2009
- Odent T, Langlais J, Glorion C, Kassis B, Bataille J, Pouliquen JC: Fractures of the Odontoid Process: A Report of 15 Cases in Children Younger Than 6 Years. *J of Pediatr Orth* 51-54, 1999
- Oral R, Rahhal R, Elshershari H, Menezes AH: Intentional Avulsion Fracture of the Second Cervical Vertebra in a Hypotonic Child. *Pediatric Emergency Care* 22(5):352-354, 2006
- Reinges M.H.T, Mayfrank L, Rohde V, Spetzger U, Gilsbach J.M: Surgically treated traumatic synchondrotic disruption of the odontoid process in a 15-month-old girl. *Child's Nerv Syst* 14: 85-87, 1998
- Schwarz N: Fractures of the Odontoid in Children. *Eur J Trauma*, 27:49-57, 2001
- Song JK: Anterior screw fixation using Herbert Screw for Type II Odontoid Process Fracture. *J Korean Neurosurg Soc* 37:345-349, 2005
- Subach BR, Morone MA, Haid RW Jr, Mc Laughlin MR, Rodts GR, Comey CH: Management of acute odontoid fractures with single-screw anterior fixation. *Neurosurgery* 45:812-819, 1999
- Swoboda B, Hirschfelder H, Hohmann D: Atlantoaxial instability in a 7-year-old boy associated with traumatic disruption of the ossiculum terminale (apical odontoid epiphysis). *Eur Spine J* 4(4): 248-251, 1995
- Uemura K, Matsumura A, Noguchi S, Shibata T, Ito M, Kobayashi E et al.: Posterior Fusion for Odontoid Fracture in an infant. *Neurol Med Chir (Tokyo)* 36:175-178, 1996
- Viswanathan A, Whithead W, Luerssen T, Illner A, Jea A: 'Orthotopic' ossiculum terminale persists and atlantoaxial instability in a child less than 12 years of age: a case report and review of the literature. *Cases Journal* 2:8530, 2009
- Wang J, Vokshoor A, Kim S, Elton S, Kosnik E: Pediatric Atlantoaxial Instability: Management with Screw Fixation. *Pediatr Neurosurg* 30:70-78, 1999
- Zapałowicz K, Radek M, Radek A: Direct fixation of the odontoid fracture in a child. *Neurol Neurochir Pol* 38(4):317-321, 2004

Manuscript submitted November 01, 2012.

Accepted January 30, 2013.

Address correspondence to: Yusuf Kurtulus Duransoy, Celal Bayar University, School of Medicine, Department of Neurosurgery, Manisa, Turkey

Phone: +90 236 233 33 96

email: ykduransoy@hotmail.com